



University of  
**Pittsburgh**

Department of Anesthesiology  
and Perioperative Medicine

# RESEARCH

---

Case Reports



# **How to Write Case Reports and Case Series**

# Objectives



Upon the completion of this PBLD, you will be able to:

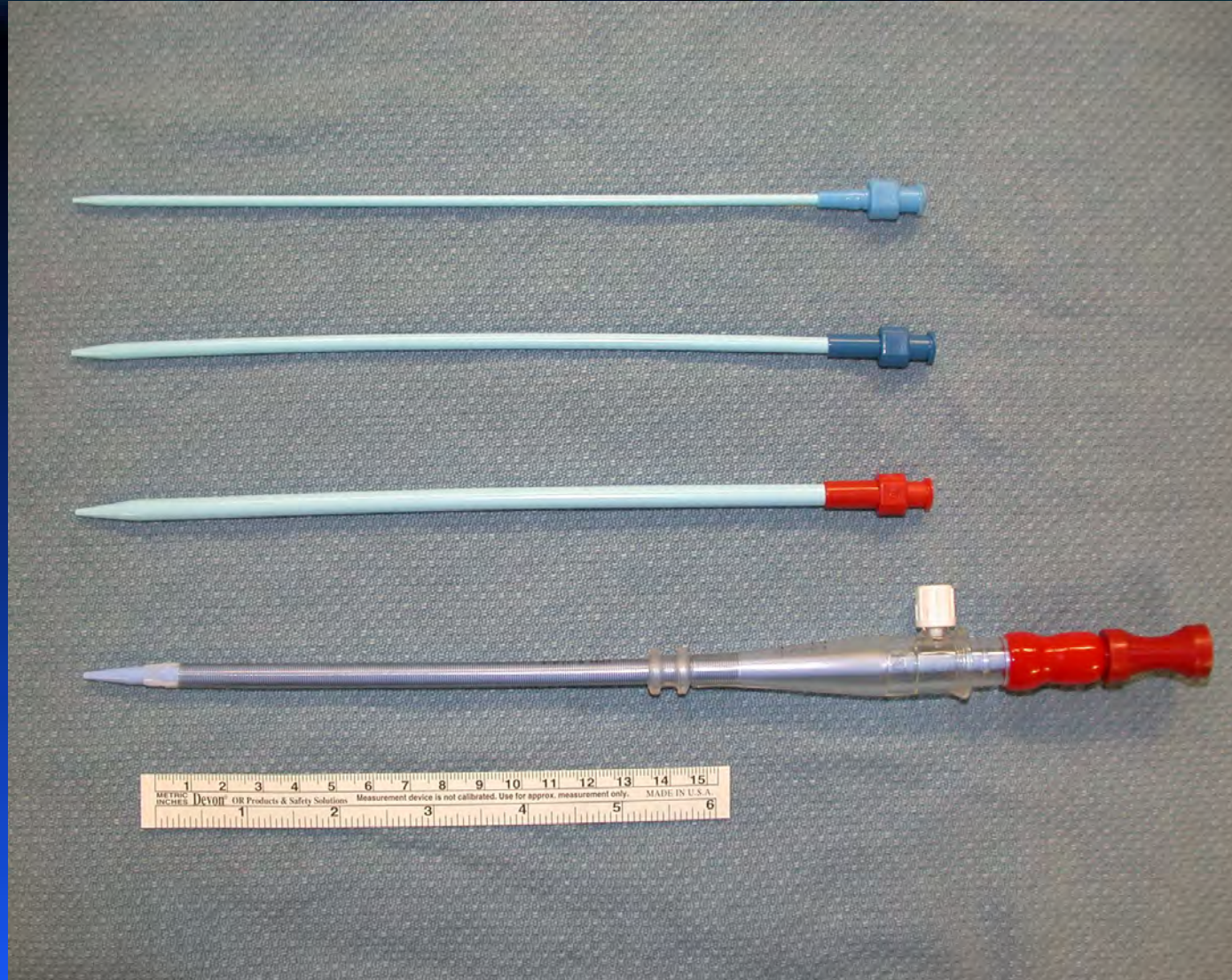- Write case reports
- Discuss the importance of data security

# Something Extraordinary Happened in the OR....

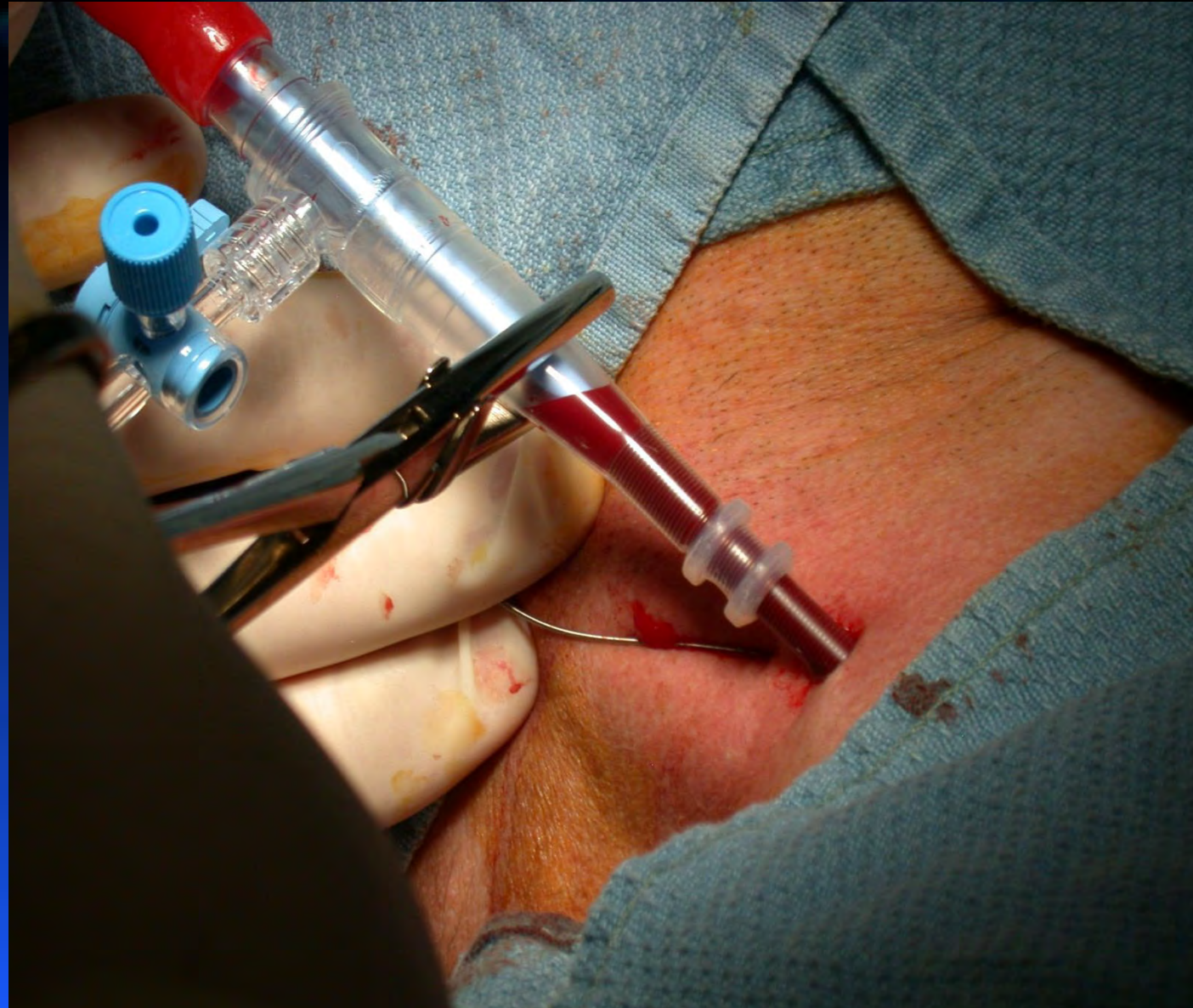


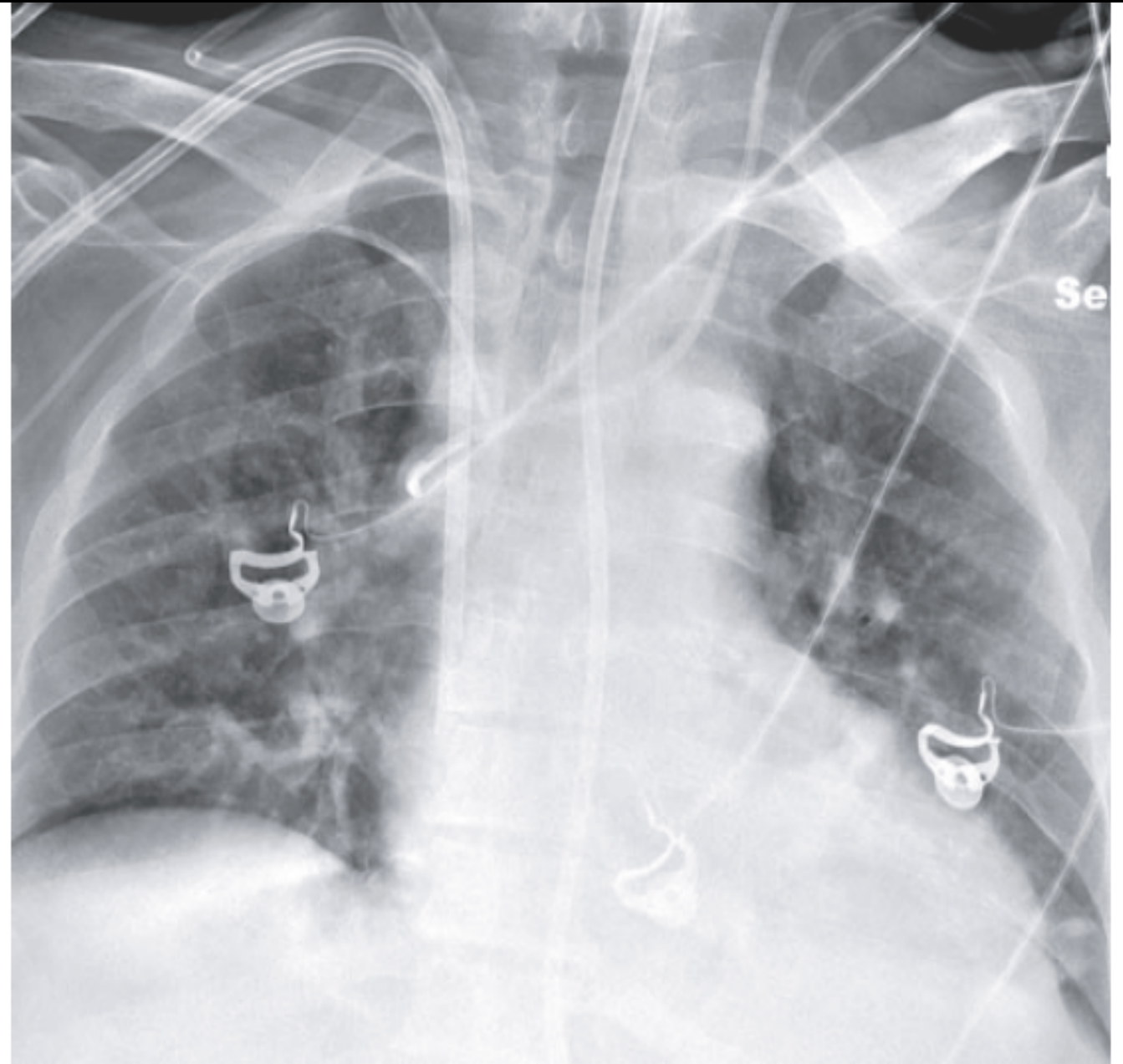
- An adult liver transplantation case assisted with a veno-venous bypass
- A veno-venous return cannula (18 Fr) was inserted via the left jugular vein
- It migrated into the persistent left SVC of the patient and resulted in the massive left sided hemothorax.

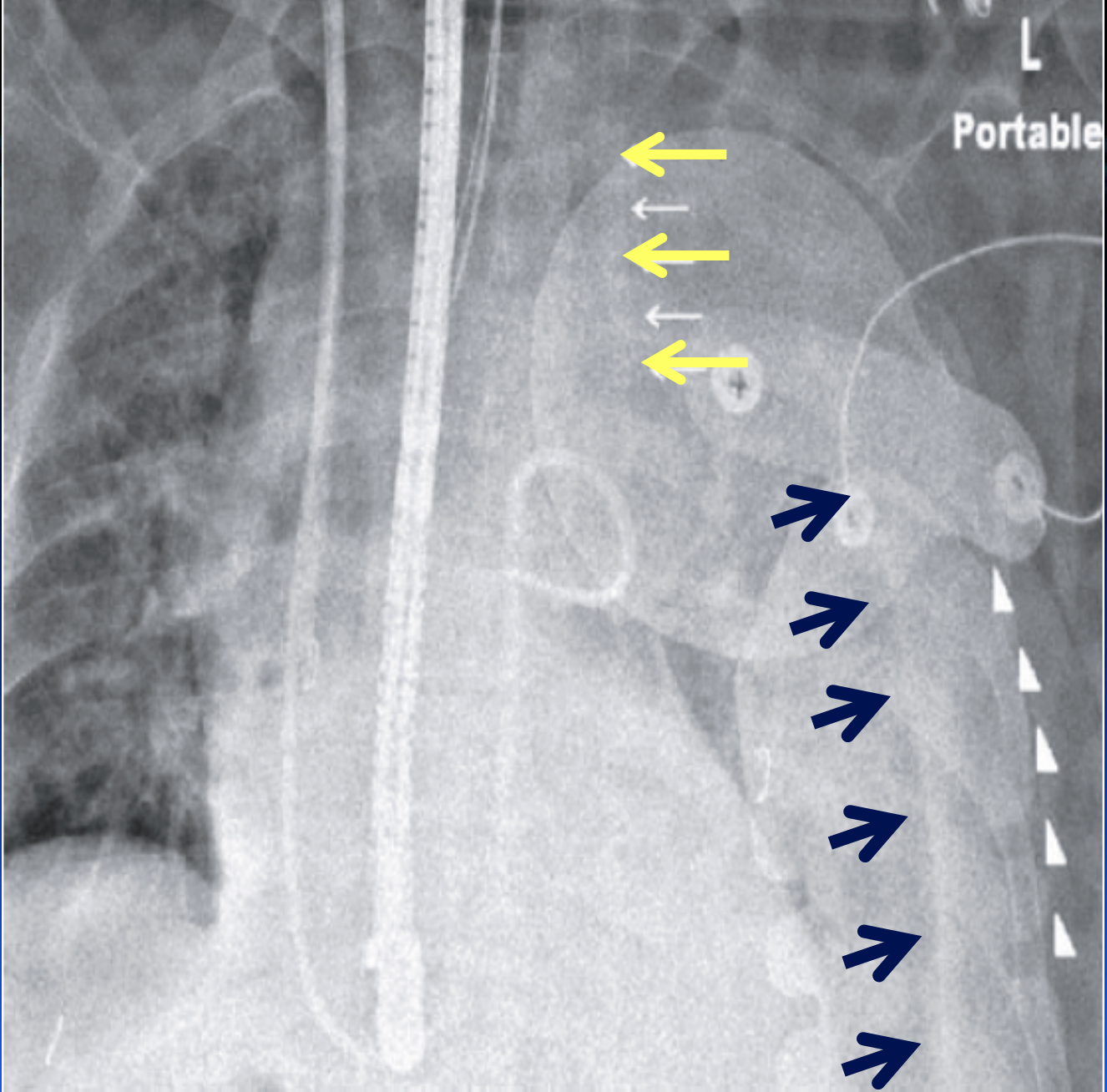
# Femoral Arterial Cannula®, (18 Fr x 15 cm, Baxter)



# Insertion of an 18 Fr. Cannula via RIJ

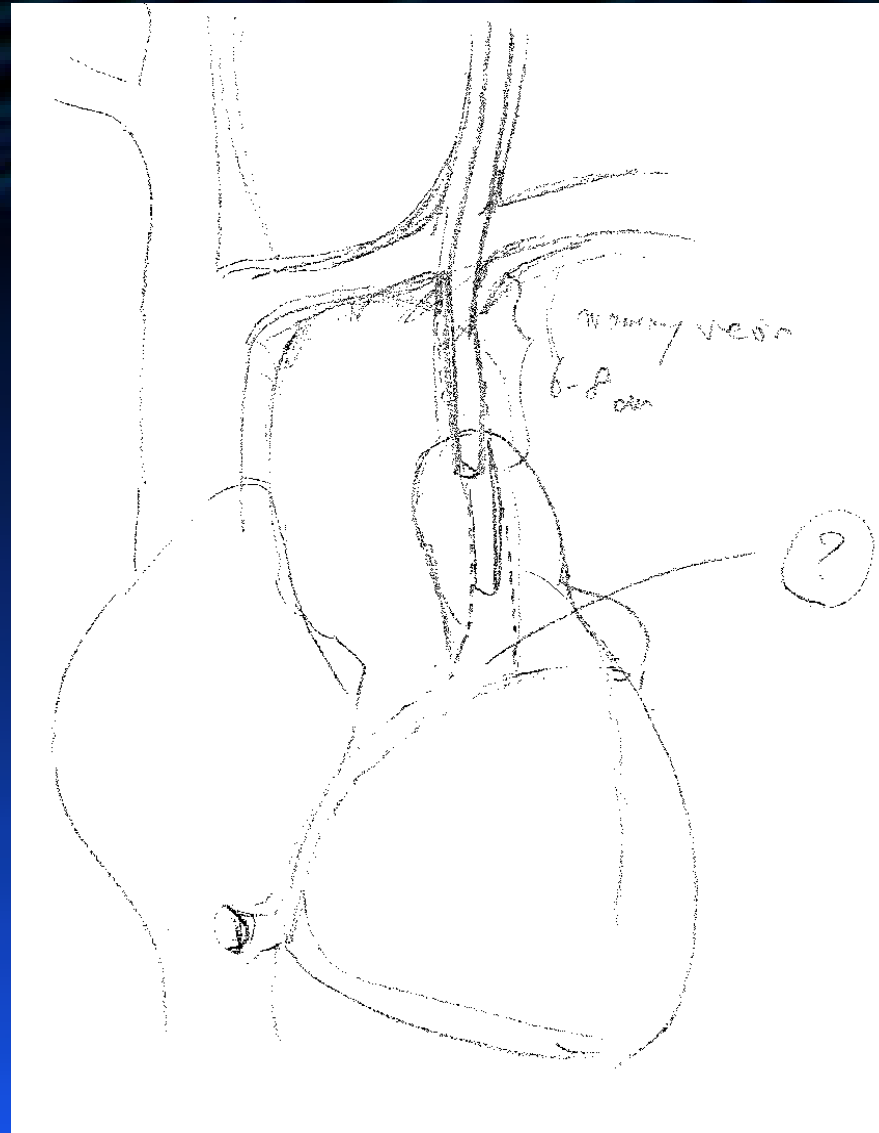








# Surgical Removal of the VVB Cannula





## Question

Should Kristin get an IRB approval to report the case?



# NO

because a case report is not research



## Question

“So, Kristin does not need any approval, right?”



## AUTHORIZATION FOR RELEASE OF PROTECTED HEALTH INFORMATION

I authorize \_\_\_\_\_ to release information from the record of:  
Name of Facility/Person

\_\_\_\_\_ to  
Patient Name Birth Date SSN/MR#  
\_\_\_\_\_  
Name of Facility/Person Phone Fax  
\_\_\_\_\_  
Facility/Person Address

for the purpose of (PROVIDE A DETAILED DESCRIPTION): \_\_\_\_\_

**Parts 1 and 2 must be completed to properly identify the records to be released.**

**1. Type of records to be released and approximate date(s) of service (check all that apply):**

- Inpatient     Emergency Dept    Dates: \_\_\_\_\_  
 Outpatient     Physician Office/Clinic

I authorize the release of: (check all that apply)  Mental Health Information     Drug and Alcohol Information,  
contained in the records indicated above.

**2. Specific information to be released (check all that apply):**

- |   |  |   |
|---|--|---|
| <input type="checkbox"/> Consults                       | <input type="checkbox"/> Medical History & Physical Exam | <input type="checkbox"/> Physician Orders               |
| <input type="checkbox"/> Discharge Summary/Instructions | <input type="checkbox"/> Medication Records              | <input type="checkbox"/> Progress Notes                 |
| <input type="checkbox"/> Laboratory Reports/Tests       | <input type="checkbox"/> Operative Report                | <input type="checkbox"/> Psychiatric/Psychological Eval |
| <input type="checkbox"/> Mammography Report             | <input type="checkbox"/> Pathology Report                | <input type="checkbox"/> Radiology Report               |
| <input type="checkbox"/> Emergency Dept. Report         | <input type="checkbox"/> EKG Report(s)                   |   |
| <input type="checkbox"/> Other: _____                   |  |   |

**HIV-related information contained in the parts of the records indicated above will be released through this authorization unless otherwise indicated.     Do not release**



## Question

How can Kristin evaluate whether the case is worthwhile to report?



<http://www.ncbi.nlm.nih.gov/pubmed>

“Venovenous bypass, complication”



## Question

How do you write the title of the case?



# List the key words of the case

Liver transplantation

VVB cannula

Accidental Insertion

Persistent left superior vena cava

# Title

*Accidental Insertion of a Percutaneous Veno-Venous  
Bypass Cannula into a Persistent Left Superior Vena  
Cava in a Patient Undergoing Liver Transplantation*



## Question

How do you write the abstract  
of the case report?

# Abstract



- Key words?
- What happened in a nutshell?
  - What happened in detail?
  - Main message?

# Abstract - Purpose

## Key words?

*Persistent left superior vena cava (PLSVC) is a rare congenital vascular abnormality found in 0.3% of the general population.*

## What happened in a nutshell?

*We report herein a rare complication involving the accidental insertion of a large bore cannula into the PLSVC during liver transplantation (LT).*

# Abstract - Clinical Features

## What happened in detail?

- *A 63-yr-old man with primary sclerosing cholangitis for LT.*
- *insertion of an 18 French cannula for venovenous bypass (VVB) was performed via the left IJV*
- *Upon initiation of VVB, profound systemic hypotension*
- *A chest x-ray confirmed a malposition of the VVB cannula with a large left hemothorax.*
- *A mini-sternotomy was performed for removal of the VVB cannula, which was found to be inserted in the PLSVC.*

# Abstract - Conclusion

## Main message?

*Malpositioning of a venous cannula in PLSVC should be anticipated as one of the potential complications of vascular access via the left internal jugular vein.*



## Question

What elements are included  
in case reports?



# Three Elements of Case Reports



1. Introduction

2. Description of the case

3. Discussion

# Three Elements of Case Reports



## 1. Introduction

What happened?

What is unique?

Why do I have to read your case report?

# Introduction

Issues specific to venous cannulation via the left internal jugular vein (IJV) in comparison with the right IJV include presence of a thoracic duct orifice, higher lung cupola, smaller vascular size, and a greater tendency for the left IJV to lie anterior rather than lateral to the carotid artery.<sup>1</sup> More importantly, when inserting larger less pliable catheters, the more angulated path from the left IJV to the right atrium can potentially cause the cannula to migrate to the other vessels or even to perforate the venous wall.

We report herein a rare complication which occurred during left IJV cannulation, namely, accidental insertion of an 18 French (Fr.) cannula for venovenous bypass (VVB) into a persistent left superior vena cava (PLSVC) during liver transplantation (LT), which resulted in a left hemothorax and required surgical repair.

The patient gave his consent for publication of this case report.

# Three Elements of Case Reports

1. Introduction

2. Description of the Case

Details of what happened in the case

Preop – Intraop – Postop

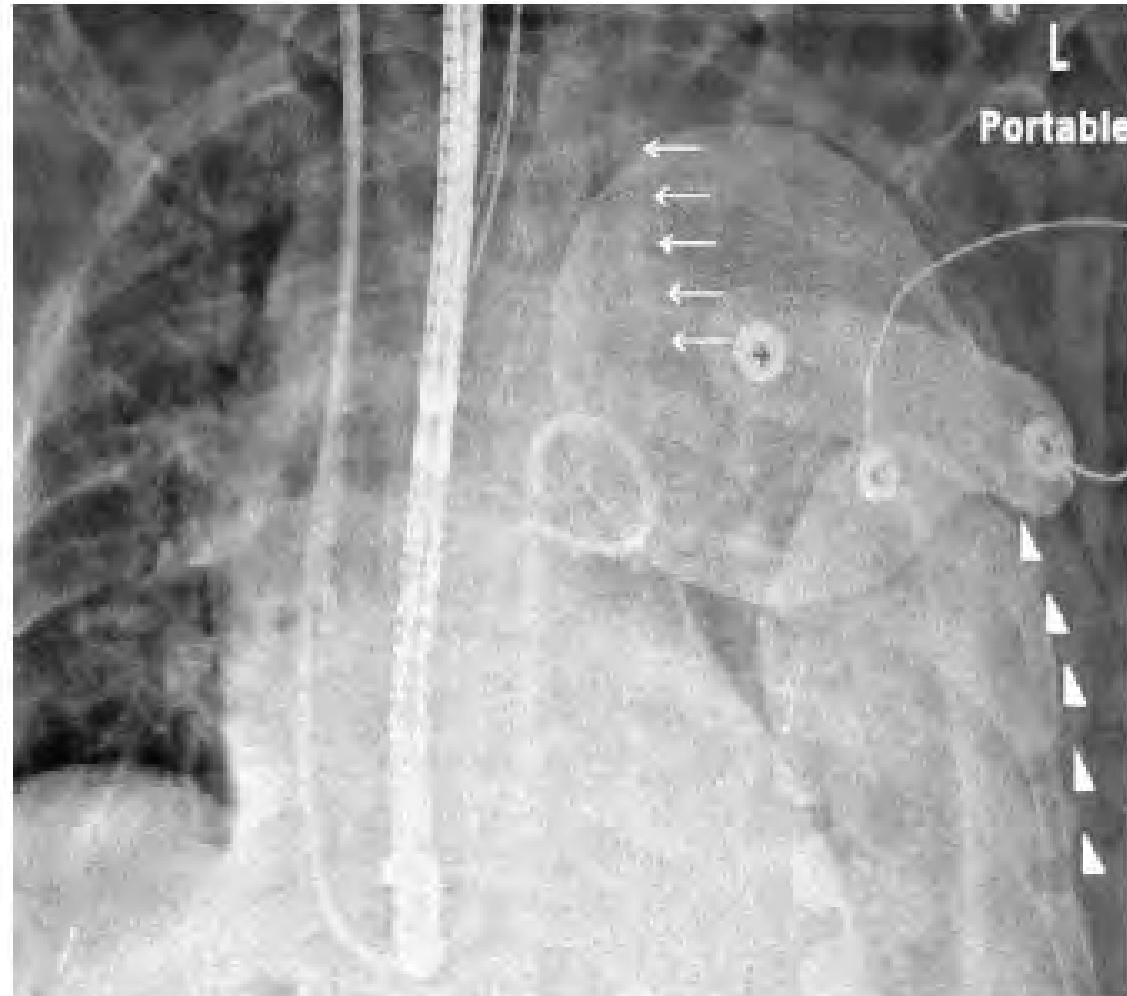
# Description of the Case

## Case report

A 63-yr-old man with primary sclerosing cholangitis presented for LT. His medical condition was complicated with a recent history of sepsis and renal failure requiring hemodialysis. His model for end-stage liver disease score was 37. Prior to the LT, transthoracic echocardiography (TTE) showed a normal left ventricle with ejection fraction of 55-60%, mild left atrial enlargement, and normal right cardiac chambers. Notably, his coronary sinus was not enlarged. His preoperative vascular access included a tunnelled dialysis catheter via the right IJV and a triple

# Description of the Case (cont.)

After induction of general anesthesia, a central venous line with a Swan-Ganz catheter was inserted via the right IJV. Standard practice in this institution was to place a percutaneous VVB return cannula for LT cases.<sup>2</sup> Given the potential difficulty of inserting the return cannula via the right IJV in the presence of the tunnelled dialysis catheter, the cannula was placed via the left IJV. An 18 Fr. Fem-Flex Duraflo Treated Femoral Arterial Cannula® (Baxter, Irvine, CA, USA) was inserted via the left IJV in the following manner: a long guidewire was first inserted through the existing triple lumen catheter in the left IJV. After the removal of the triple lumen catheter, the VVB cannula was inserted using the guidewire. No difficulty was noted in exchanging the triple lumen catheter for the VVB cannula. After the insertion, smooth blood withdrawal as well as smooth infusion of normal saline was observed via the VVB cannula. Vital signs were stable throughout this process.



**Fig. 2** The postoperative chest *x-ray* demonstrated a large left pleural effusion (dots). The position of the venovenous bypass return cannula (squares) via the left internal jugular vein was coursing through the left internal jugular vein and straight down toward the mediastinum

# Three Elements of Case Reports

1. Review of background knowledge
2. Review of the similar cases
3. Uniqueness of the case
4. Recommendations in similar cases in the future
5. Conclusion

## 3. Discussion



# 1. Review of background knowledge

## Discussion

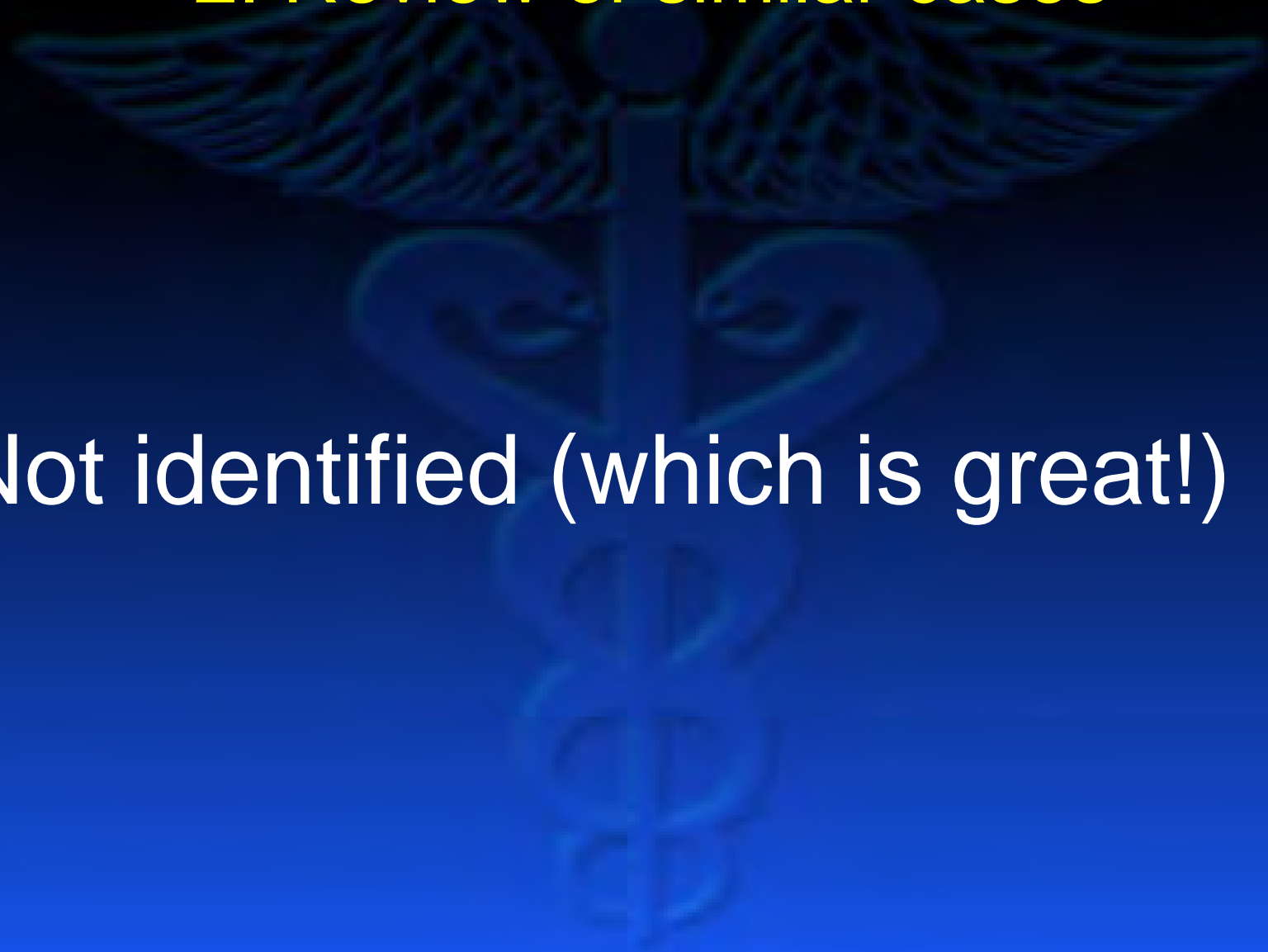
Persistent left superior vena cava is the most common vascular anomaly of the thoracic venous system. Since the original description in 1950,<sup>3</sup> over 200 cases have been reported.<sup>4-6</sup> This anomaly has been found in 0.3% of the general population, while a higher incidence (4.5%) has been noted in patients with congenital heart disease.<sup>7</sup> Persistent left superior vena cava is often discovered when an enlarged coronary sinus is seen on echocardiography, since the sinus is the routine drainage route of PLSVC. Gonzalez-Juanatey *et al.* found that ten in 9,075 patients (0.11 %) examined by TTE had a PLSVC along with a dilated coronary sinus.<sup>5</sup> In rare cases, however, direct drainage into the left atrium has been reported.<sup>8,9</sup> There was some variability in the thoracic vasculature, most notably the absence of the left innominate vein in 50-65% of PLSVC cases.<sup>1,5</sup>

# 1. Review of background knowledge

Although some reports have associated PLSVC with sinus bradycardia and sinus arrest,<sup>10</sup> the discovery of a PLSVC is primarily incidental. The presence of a dilated coronary sinus with echocardiography in the absence of elevated right atrial pressure would raise the suspicion, and further investigation using venography via the left jugular vein or the peripheral vein of the left arm would confirm diagnosis of a PLSVC.<sup>6</sup>

## 2. Review of similar cases

Not identified (which is great!)



### 3. Uniqueness of the case

In our case, the index of suspicion for a PLSVC was extremely low given the normal left innominate vein, which accommodated a triple lumen catheter via the left IJV (Fig. 1), and a non-dilated coronary sinus seen during echocardiography.

We chose the left IJV for VVB return cannula placement due to the presence of a pre-existing hemodialysis catheter in the right IJV. Interestingly, insertion of the VVB cannula was accomplished without apparent difficulty using a guidewire through the pre-existing triple lumen catheter.

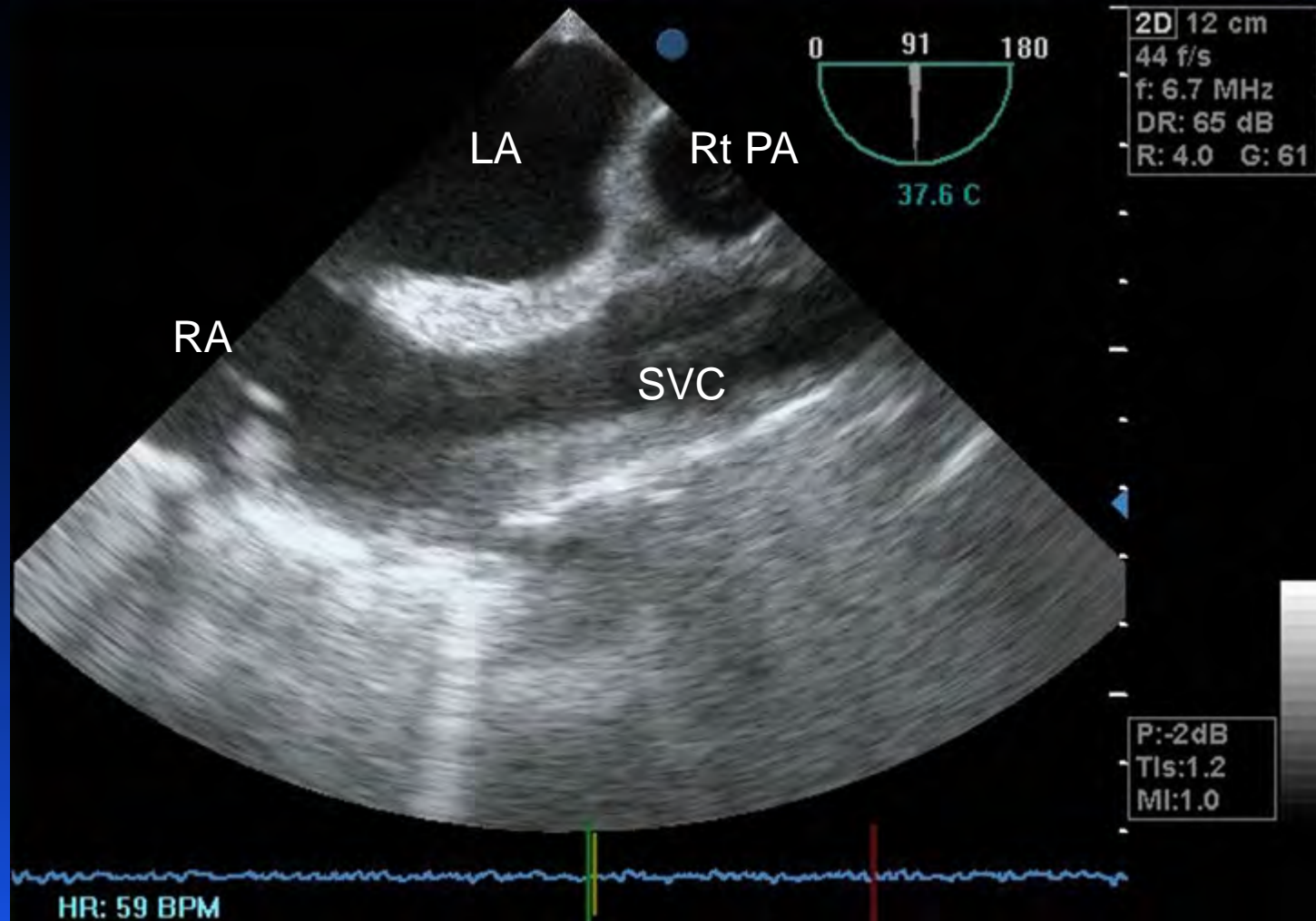
## 4. Recommendations in similar cases in the future

This case emphasizes the risk of central line insertion via the left IJV. The safety of inserting such a large bore VVB cannula via the left IJV rather than via the right IJV has not been fully established.<sup>11</sup> Alternate management options might have included placement of the VVB cannula via an axillary venous cut-down or elimination of the VVB with a piggyback method. Recently, the need for the VVB for LT has been questioned,<sup>12</sup> and authors of a large retrospective case series suggested the potential benefit of the retrohepatic caval preservation technique (or piggyback technique) without VVB over the use of VVB.<sup>13</sup>

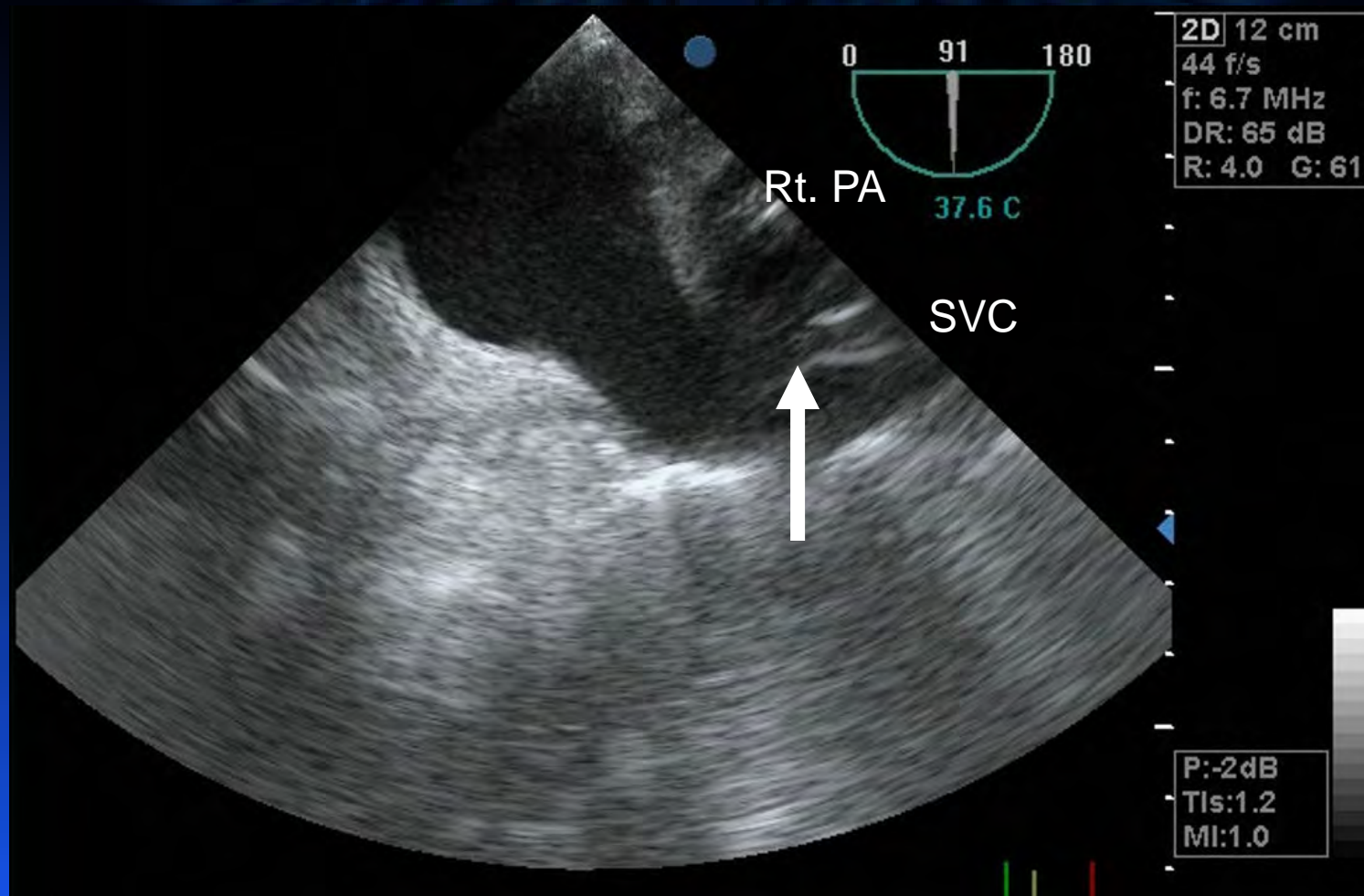
## 4. Recommendations in similar cases in the future

Furthermore, the placement of the VVB cannula should be confirmed either by direct TEE visualization of the VVB cannula tip or by performing a “bubble test” through the VVB cannula.<sup>2</sup> The latter test would have demonstrated the immediate appearance of bubbles in the right atrium via the coronary sinus instead of via the superior vena cava and ultimately would have led to the diagnosis of a malpositioned cannula in the PLSVC. In this particular case, we acknowledge that we could have prevented the malposition of the cannula in the PLSVC by placement of TEE prior to the line exchange via the left IJV and identification of the guidewire in the superior vena cava throughout the VVB cannula placement. We also recognize that an attempt to identify the tip of the VVB cannula in the left innominate vein using the upper esophageal sagittal view of TEE could have suggested a potential malposition of the cannula. In addition, we acknowledge that the bubble test was not performed in this case.

# TEE Bicaval View

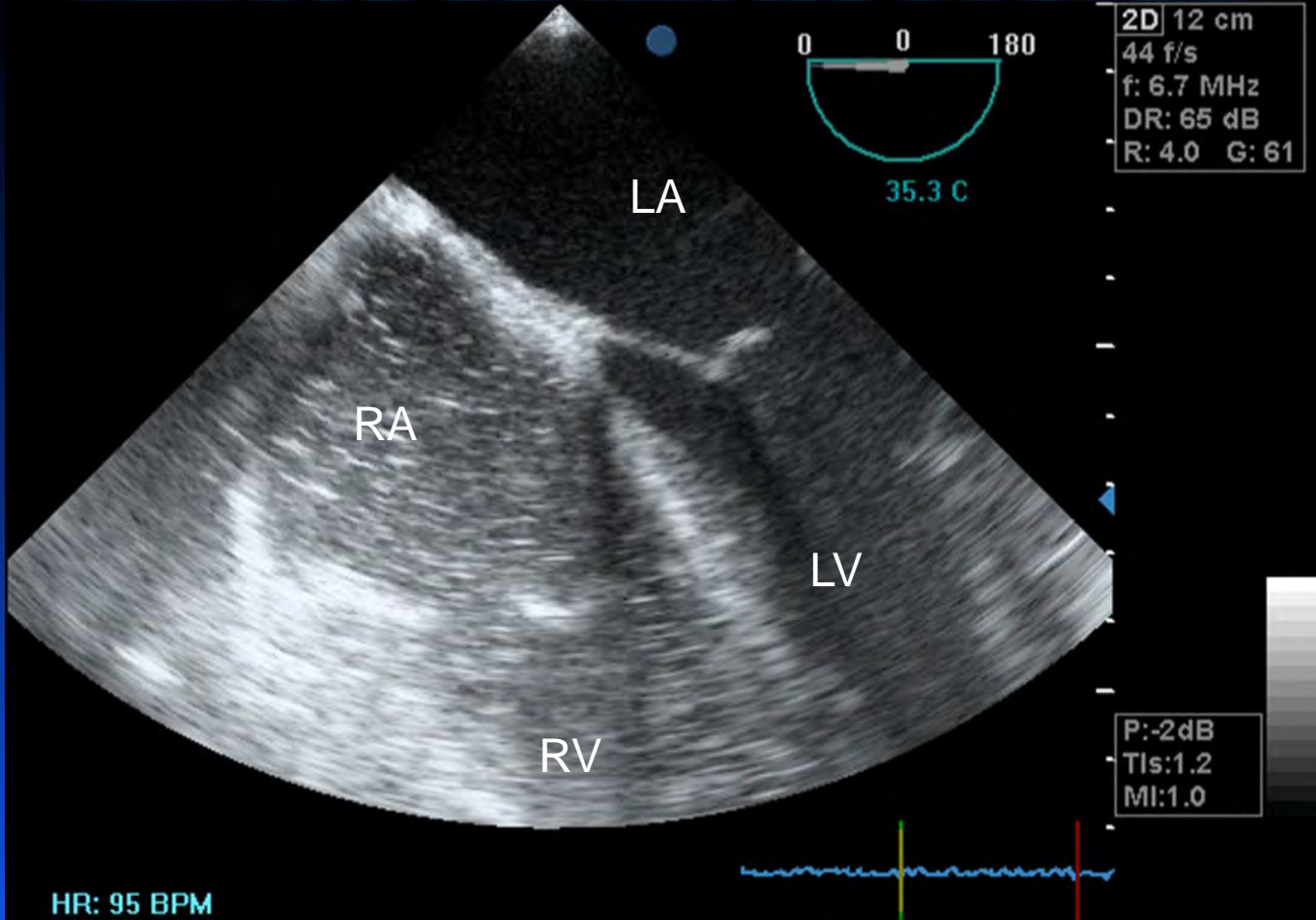


# VVB Cannula Position





# Bubble Test



## 5. Conclusion

In conclusion, all anesthesiologists should be aware that inadvertent placement of a catheter into the PLSVC is a potential complication when using the left IJV as an insertion site particularly when larger more rigid catheters are used. Placing a large bore cannula for VVB via the left IJV should be attempted only in rare cases and should be performed with extreme caution.

**Acknowledgement** The authors thank Christine M. Heiner BA (Scientific Writer, Department of Anesthesiology/Department of Surgery, University of Pittsburgh School of Medicine) for her editorial assistance with the manuscript.

**Research/Financial Support** Support was received solely from the above institutional and departmental sources.

**Conflict of interest** None declared.

## References

1. *Webb WR, Gamsu G, Speckman JM, Kaiser JA, Federle MP, Lipton MJ.* Computed tomographic demonstration of mediastinal venous anomalies. *ARJ Am J Roentgenol* 1982; 139: 157-61.
2. *Sakai T, Gligor S, Diulus J, McAfee R, Marsh JW, Planinsic RM.* Insertion and management of percutaneous veno-venous bypass cannula for liver transplantation: a reference for transplant anesthesiologists. *Clinical Transplantation* 2010; 24: 585-91.

CASE REPORTS/CASE SERIES

## **Accidental insertion of a percutaneous venovenous cannula into the persistent left superior vena cava of a patient undergoing liver transplantation**

**Insertion accidentelle d'une canule veino-veineuse percutanée dans la veine cave supérieure gauche persistante d'un patient subissant une greffe hépatique**

**Kristin L. Schreiber, MD, PhD** · Takashi Matsusaki, MD, PhD ·  
Brian C. Bane, MD · Christian A. Bermudez, MD · Ibtesam A. Hilmi, MBChB ·  
Tetsuro Sakai, MD, PhD



## Case Report by a CBY



- As a CBY resident, Pat witnessed a 72-yr old man who underwent parotid gland resection and developed a five-hour paralysis after a dose of succinylcholine.
- He plans to submit a paper about the experience as an ASA medically challenging case.

Is this case worthwhile to report?

<http://www.ncbi.nlm.nih.gov/pubmed>

pseudocholinesterase deficiency

33 papers

40 cases



## Question

Should Pat abandon his plan?

# A Case Report and Literature Review!

ISSN 1741-9723  
© Am J Case Rep, 2015; 16: 637-644  
DOI: 10.12659/AJCR.895235

Living Donor Liver Transplantation for  
Unresectable Liver Adenomatosis Associated  
with Congenital Absence of Portal Vein:  
**A Case Report and Literature Review**

**ECMO support for right main bronchial  
disruption in multiple trauma patient with brain  
injury—a case report and literature review**

Perfusion  
2015, Vol. 30(5) 403–406  
© The Author(s) 2014  
Reprints and permissions:  
sagepub.co.uk/journalsPermissions.nav  
DOI: 10.1177/0267659114554326  
prf.sagepub.com  


Hamaya et al. *Journal of Medical Case Reports* (2015) 9:111  
DOI 10.1186/s13256-015-0593-9



JOURNAL OF MEDICAL  
CASE REPORTS

**CASE REPORT**

**Open Access**

Polytetrafluoroethylene fume-induced pulmonary  
edema: **a case report and review of the literature**

# Pseudocholinesterase Deficiency: A Case Report and Literature Review

**Patrick J. Hackett, Tetsuro Sakai**

Department of Anesthesiology, University of Pittsburgh School of Medicine, Pittsburgh, USA.  
Email: sakait@upmc.edu

Received July 1<sup>st</sup>, 2012; revised August 9<sup>th</sup>, 2012; accepted August 27<sup>th</sup>, 2012



## ABSTRACT

A 72-year-old male underwent neck dissection and parotidectomy with facial nerve preservation. Endotracheal intubation was facilitated with succinylcholine. Prolonged muscle paralysis which was first detected after failure to stimulate the facial nerve with electrocautery, lasted five hours. Laboratory tests indicated pseudocholinesterase (PChE) deficiency. A thyroidectomy one month later was performed uneventfully using rocuronium as a muscle relaxant. Literature review revealed a total of 40 PChE deficiency cases being reported since 1956.

**Keywords:** Prolonged Paralysis; Succinylcholine; Pseudocholinesterase Deficiency; Dibucaine Number; Case Review



**Table 2. Summary of the reported cases of pseudocholinesterase deficiency.**

ID	Year	Age <sup>3</sup> /Sex	Procedure	Agent	Additional agent	Clinical sign	Ventilation support (min)	FFP
1	1960 [29]	1.25/F	Lumbar meningocele	SCh	None	PA	190	No
2	1962 [37]	7/F	Tonsillectomy	SCh	None	PA	75	No
3	1962 [37]	6/M	Tonsillectomy	SCh	None	PA	150	No
4	1962 [37]	4/F	Tonsillectomy	SCh	None	PA	270	No
5	1965 [28]	73/M	Laparotomy	SCh	None	PA	50	No
6	1966 [6]	24/M	Scapula tumor biopsy	SCh	None	PA	210	Yes
7	1966 [6]	17/M	Laminectomy	SCh	None	PA	240	No
8	1967 [35]	23/W	Bronchoscopy	SCh	None	PA	180	No
9	1968 [36]	41/M	Gastroscopy	SCh	None	PA	100	No
10	1973 [27]	47/F	Cholecystectomy	SCh	None	PA	630	No

30	2007 [14]	39/M	Digit amputation	SCh	None	PP	150	No
31	2007 [12]	67/M	Electro convulsive therapy	SCh	None	PP	150	No
32	2007 [7]	35/F	Endotracheal intubation	None <sup>b</sup>	None	None	Extubated on day 13	No
33	2009 [22]	80/M	Ventro-peritoneal shunt	None	None	n/a	n/a	No
34	2009 [23]	30/F	Cesarean section	SCh	None	PP	360	No
35	2010 [30]	70/M	Electro convulsive therapy	SCh	None	PP	240	No
36	2010 [32]	26/F	Cesarean section	SCh	None	PA	540	No
37	2011 [19]	26/M	Nasal septum repair	Mivac	None	PP	420	No
38	2011 [19]	7/M	Tonsillectomy	Mivac	None	PP	240	No
39	2011 [20]	60/M	Electro convulsive therapy	SCh	None	PP	120	No
40	2011 [21]	26/M	Electro convulsive therapy	None	Roc	n/a	n/a	No
<b>41</b>	<b>Present case</b>	<b>72/M</b>	<b>Parotidectomy</b>	<b>SCh</b>	<b>None</b>	<b>PP</b>	<b>300</b>	<b>No</b>

Note: <sup>a</sup>Year-old (unless otherwise indicated); <sup>b</sup>Known family history of PChE-D: No paralytic was used; Abbreviations: F, female; M, male; wks, weeks old; TURP, transurethral resection of the prostate; SCh, succinylcholine; Mivac, mivacurium; Atrac, atracurium; Roc, rocuronium; PA, prolonged apnea; PP, prolonged paralysis; FFP, fresh frozen plasma.

Table 3. Summary of the reported cases of pseudocholinesterase deficiency (continued).

ID	Initial PChE (IU/L)	Dibucaine number	Cause	Family history of PChE-D	Follow-up
1	25 <sup>c</sup>	n/a	Genetic	Yes	None
2	60.5 <sup>c</sup>	n/a	Genetic	Yes	Family testing with PChE-D
3	68.5 <sup>c</sup>	n/a	Genetic	Yes	Family testing with PChE-D
4	22 <sup>c</sup>	n/a	Genetic	Yes	Family testing with PChE-D
5	5 <sup>d</sup>	n/a	Amoebic liver disease	No	None
6	2 <sup>e</sup>	n/a	Unknown	No	None
7	1 <sup>e</sup>	n/a	Unknown	Unknown	None
8	12.3 <sup>c</sup>	n/a	Genetic	No	Family testing with PChE-D
9	n/a	n/a	Unknown	Unknown	None
10	0.22-0.84 pH/hr	n/a	Unknown	Unknown	None
11	800	27	AH	Yes <sup>f</sup>	None
12	"Normal"	"Very low"	AH	Yes <sup>g</sup>	None
13	1300	"Normal"	Diethylstilbestrol	Unknown	PChE normalized after d/c diethylstilbestrol
14	40	32	Genetic	Unknown	PChE 84, dibucaine 27 (6 weeks postpartum)

Table 3. Summary of the reported cases of pseudocholinesterase deficiency (continued).

ID	Initial PChE (IU/L)	Dibucaine number	Cause	Family history of PChE-D	Follow-up
30	2765	23	AH	No	None
31	375	19	AH	Unknown	None
32	n/a	n/a	Genetic	Yes	None
33	5	n/a	Unknown	Unknown	None
34	1123	n/a	Genetic	Unknown	PChE 1479 IU/L (3 years post-op)
35	n/a	n/a	Unknown	Unknown	None
36	<100	n/a	Unknown	Unknown	None
37	3393	n/a	Genetic	No	None
38	2558	n/a	Genetic	No	None
39	1125	23	Genetic	No	None
40	2942	n/a	Unknown	Unknown	None
41	1080	n/a	Genetic	Unknown	PChE 1100 IU/L (4 weeks post-op)

Note: <sup>c</sup>μL CO<sub>2</sub>/mL; <sup>d</sup>μmol/s/mL/hr; <sup>e</sup>mM acetylcholine hydrolyzed/hr/L; <sup>f</sup>Father with heterozygosity; Mother with borderline heterozygosity; <sup>g</sup>Children with heterozygosity; <sup>h</sup>Clinical history of mother; <sup>i</sup>A reduced dosage (50% - 75%) of succinylcholine was administered to provide paralysis and allowed faster recovery; Abbreviations: PChE, pseudocholinesterase; PChE-D, pseudocholinesterase deficiency; AH, atypical PChE homozygosity; OHSS, ovarian hyperstimulation syndrome; HELLP, hemolysis, elevated liver enzymes, low platelets syndrome.

# Summary



Case Report

Evaluation

Consent

Three parts (Introduction / Case Report / Discussion)

Case Series